



Anterior cruciate ligament reconstruction is associated with greater tibial tunnel widening when using a bioabsorbable screw compared to an all-inside technique with suspensory fixation

Edoardo Monaco¹ · Mattia Fabbri¹ · Andrea Redler¹ · Edoardo Gaj¹ · Angelo De Carli¹ · Giuseppe Argento² · Adnan Saithna³ · Andrea Ferretti¹

Received: 16 June 2018 / Accepted: 29 October 2018

© European Society of Sports Traumatology, Knee Surgery, Arthroscopy (ESSKA) 2018

Abstract

Purpose To compare clinical outcomes and tunnel widening following anterior cruciate ligament reconstruction (ACLR) performed with an all-inside technique (Group A) or with a bioabsorbable tibial screw and suspensory femoral fixation (Group B).

Methods Tunnel widening was assessed using computed tomography (CT) and a previously validated analytical best fit cylinder technique at approximately 1-year following ACLR. Clinical follow-up comprised evaluation with IKDC, KSS, Tegner, Lysholm scores, and knee laxity assessment.

Results The study population comprised 22 patients in each group with a median clinical follow-up of 24 months (range 21–27 months). The median duration between ACLR and CT was 13 months (range 12–14 months). There were no significant differences in clinical outcome measures between groups. There were no differences between groups with respect to femoral tunnel widening. However, there was a significantly larger increase in tibial tunnel widening, at the middle portion, in Group B (2.4 ± 1.5 mm) compared to Group A (0.8 ± 0.4 mm) ($p=0.027$), and also at the articular portion in Group B (1.5 ± 0.8 mm) compared to Group A (0.8 ± 0.8 mm) ($p=0.027$).

Conclusion Tibial tunnel widening after ACLR using hamstring tendon autograft is significantly greater with suspensory femoral fixation and a bioabsorbable tibial interference screw when compared to an all-inside technique at a median follow-up of 2 years. The clinical relevance of this work lies in the rebuttal of concerns arising from biomechanical studies regarding the possibility of increased tunnel widening with an all-inside technique.

Level of evidence III.

Keywords All-inside · ACL reconstruction · Tunnel widening · Bioabsorbable screw · Retrograde drilling

Introduction

In 1995, Morgan et al. first described all-inside anterior cruciate ligament reconstruction (ACLR) using both tibial and femoral sockets, and the avoidance of drilling complete tunnels. Although there are now many variations of all-inside ACLR, recent systematic review has demonstrated that the overall strategy is associated with low graft failure rates and significant improvements in clinical outcomes with respect to knee function, pain, stability, and patient satisfaction at short-term follow-up. However, there are only a small number of comparative studies [8, 17, 23] and therefore the proposed benefits over standard techniques remain unproven. One of the theoretical benefits is a decrease in the incidence of tunnel widening (TW) [12]. This is a phenomenon that

✉ Edoardo Monaco
edoardomonaco76@gmail.com

¹ Orthopaedic Unit and Kirk Kilgour Sports Injury Center, S. Andrea Hospital, University of Rome “Sapienza”, Via di Grottarossa 1035-1039, 00189 Rome, Italy

² Department of radiology, S. Andrea Hospital, University of Rome “Sapienza”, Rome, Italy

³ Southport and Ormskirk Hospitals NHS Trust, Town Lane, Southport, England, UK

frequently occurs after ACLR, particularly with hamstring tendon grafts. It is reported to occur predominantly in the first 6 weeks after surgery. The main clinical concern with tunnel widening is that in the event of graft failure, enlargement of tunnels can compromise single stage revision ACLR, and result in the need for bone grafting and a two-stage procedure.

The pathophysiology of tunnel widening is multifactorial. Mechanical, surgical and biological factors have all been implicated in the etiology [4, 5, 16, 28]. However, the interaction between factors is not completely understood and for this reason, the rate of tunnel widening after ACLR must be specifically evaluated for different variations of surgical technique. To the knowledge of the authors only one previous study has specifically evaluated tunnel widening after all-inside ACLR in a comparative study. Mayr et al. demonstrated that femoral tunnel widening after all-inside ACLR using suspensory fixation was significantly greater than following ACLR with aperture fixation with interference screws for both tibial and femoral tunnels [18]. Although the latter is a frequently used technique, a multi-national registry based review of contemporary practice reveals that in Denmark, Norway, Sweden and the UK the most popular graft choice is hamstring tendon autograft fixed with an interference screw on the tibia and suspensory femoral fixation [25]. The aim of this study was therefore to compare tunnel widening following this technique against all-inside ACLR. The study hypothesis was that a significantly greater degree of tibial tunnel widening would be observed with the all-inside technique when compared to ACLR fixed with an interference screw on the tibia and suspensory femoral fixation.

Materials and methods

Patients who underwent hamstring tendon autograft ACLR for a chronic ACL rupture (> 3 months from the date of injury) with either the graftlink all-inside technique [14] or with suspensory femoral fixation and a tibial interference screw between January 2016 and June 2016 were considered for study eligibility. Patients were excluded if they had sustained a multi-ligament injury, or had a Segond fracture, but patients with meniscal and/or chondral injuries were included. Further exclusion criteria were a history of previous knee injury/surgery, patients aged over 40 years and those with a body mass index (BMI) greater than 30. Informed consent was obtained from all patients.

Surgical technique

For both surgical techniques, the tunnels were drilled corresponding to graft diameter. The femoral tunnel center

was located at approximately 40% of the proximal–distal distance of the lateral notch and was centered between the lateral intercondylar ridge and the posterior articular margin. This point was centered over the lateral bifurcate ridge at a distance equivalent to the planned tunnel radius, plus an additional 2.5 mm from the posterior articular cartilage. The center of the tibial tunnel was located at 40% of the medial–lateral width of the interspinous distance, in line with the posterior edge of the lateral meniscal anterior horn, approximately 15 mm anterior–posterior cruciate ligament [1].

Group A: all-inside ACLR

In the all-inside group, patients underwent ACL reconstruction performed with the graftlink technique [14]. The harvested semitendinosus tendon was quadrupled to obtain a final graft length of no more than 75 mm, and sewn in linkage with a TightRope-RT adjustable loop cortical button (Arthrex, Naples, FL, USA) and a high strength suture (No. 0 FiberWire; Arthrex, Naples, FL, USA) on each side of the graft. Standard anterolateral (AL) and anteromedial portals were used. With a standard guide set at 60–65°, a 25-mm tibial socket was created at the anatomic ACL insertion point using a specific retrodrill (Flipcutter, Arthrex, Naples, FL, USA). A 25-mm femoral socket was created with an outside-in technique using a standard guide set approximately 100°–110° and the same retrodrill as on the tibial side. Using a shuttle suture on both sides, the graft was introduced into the knee through the AM portal and fixed first on femoral side, then on tibial side with the “flip-then-fill technique” [14].

Group B: femoral suspensory fixation and tibial interference screw

Patients underwent ACLR with an outside-in technique and doubled semitendinosus and gracilis tendons (DGST) autograft. The tibial tunnel was drilled over a wire that was placed in the anatomic tibial ACL insertion point using the Arthrex footprint guide set at 60°–65° with a standard anterograde drill. On the femoral side, a 25-mm bone socket was drilled with an outside-in technique and using the Arthrex footprint guide with drill sleeve set at approximately 100°–110° employing a Flipcutter retrodrill (Arthrex, Naples, USA). The graft was then passed fixed with an adjustable loop length device on the femur (TightRope-RT Arthrex, Naples, FL, USA) and an absorbable interference screw (Deltascrew, Arthrex, Naples, FL, USA), sized 1 mm greater than graft diameter, on the tibia.

Fig. 2 **a** Right knee, 3D model of tibia, bone socket and fixation device of an all-inside technique; **b** right knee, 3D cast of tibial bone socket of an all-inside technique; **c** right knee, creation of an analytical best fit cylinder fitted to the 3D cast of the articular portion of the tibial bone socket of an all-inside technique

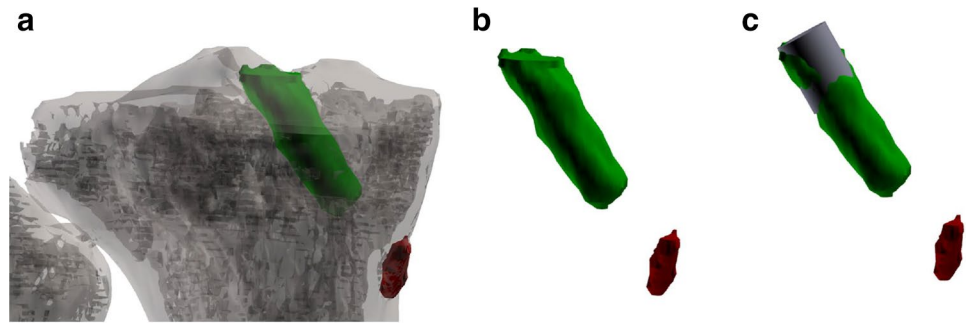
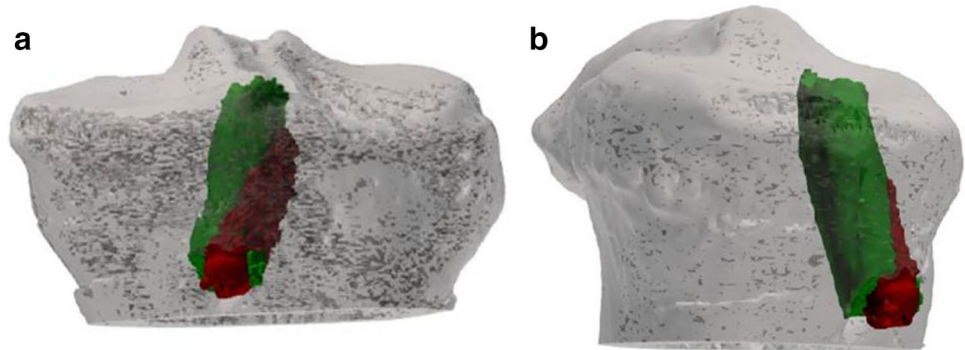


Fig. 3 Left knee, screw protrusion from the tibial bone tunnel in the control group (**a** frontal view; **b** lateral view)



Statistical analysis generated standard descriptive statistics: means, standard deviations, and proportions. The Wilcoxon test was used to evaluate differences between pre-operative and follow-up results in each group. The Mann–Whitney *U* test was applied to verify differences between the two groups. Statistical significance was set at $P < 0.05$. The Statistical Package for Social Sciences (SPSS) software version 22 was used for all calculations. A sample size calculation for a continuous outcome superiority trial was performed using the sealedenvelope.com online based software and published tunnel widening data from Mayr et al. [18]. This demonstrated that 40 patients were required to have a 90% chance of detecting, as significant at the 5% level, an increase in the primary outcome measure from $111.1 \pm 10.8\%$ (tibial tunnel widening reported by Mayr et al. [18] with an interference screw) in the control group to 122.4% (tibial tunnel widening with an all-inside technique) in the experimental group.

Results

The overall study population comprised of 44 patients (22 in each group) who underwent ACLR for a chronic ACL injury. The mean time between injury and surgery was 8 months (range 5–13 months). The median duration of clinical follow-up after ACLR was 24 months (range 21–27 months). The median duration of time between ACLR and

Table 1 Baseline characteristics

Variable	Group A	Group B	<i>P</i> value
Age	32.5 ± 6.7	31.7 ± 7.1	n.s.
Sex (M;F)	15;7	17;5	n.s.
Dominant side involvement	15	13	n.s.
Time from diagnosis to intervention (months)	7.3 ± 2	8.1 ± 3.4	n.s.
Meniscal lesions (medial;lateral)	2;3	2;4	n.s.
Condral lesions (femur;tibia)	2;0	1;0	n.s.

post-operative CT evaluation was 13 months (range 12–14 months).

The baseline characteristics of the two groups are shown in Table 1.

No significant differences were detected between the two groups with respect to any of the clinical or patient-reported outcome measures assessed. This information is summarized in Tables 2 and 3.

Radiological evaluation

Tunnel widening data are summarized in Table 4. In Group A, the mean drill diameter at T0 was 9.3 ± 0.5 . This was significantly increased at T1 by 30% to a mean femoral tunnel diameter of 12.1 ± 0.9 mm at the middle portion ($P = 0.02$), and by 28% to a mean diameter of 12 ± 1.7 mm

Table 2 Clinical outcomes

Group A	Pre-op (range)	Post-op (range)	P value
Tegner score ^a	6 (6–9)	6 (5–9)	n.s.
Lysholm score ^a	59 (31–85)	95 (74–100)	<i>P=0.01</i>
Kss for pain ^a	63 (19–87)	96 (92–100)	<i>P=0.01</i>
Kss for function ^a	80 (20–90)	100 (100)	<i>P=0.01</i>
IKDC ^a	50 (11.5–60.9)	91 (87.4–100)	<i>P=0.01</i>
KT 1000 ^b	9.5 ± 2.4 mm	1.7 ± 1.2 mm	

^aMedian (range values)

^bMean ± SD

Table 3 Clinical outcomes

Group B	Pre-op (range)	Post-op (range)	P value
Tegner score ^a	7 (6–8)	6 (6–8)	<i>P=0.02</i>
Lysholm score ^a	57 (27–81)	90 (72–100)	<i>P=0.005</i>
Kss for pain ^a	58 (19–87)	95 (92–100)	<i>P=0.005</i>
Kss for function ^a	80 (20–90)	100 (100)	<i>P=0.005</i>
IKDC ^a	50 (11.5–60.9)	94 (87.4–98.9)	<i>P=0.005</i>
KT 1000 ^b	10.1 ± 2.6 mm	2.1 ± 1.2 mm	

^aMedian (range values)

^bMean ± SD

at the articular portion (*P=0.04*). The mean tibial tunnel diameter was increased at T1 by 8% to 10.1 ± 0.6 mm at the middle portion (n.s.) and significantly increased by 9% to 10.1 ± 1 mm at the articular portion (*P=0.02*).

In Group B, the mean drill diameter at T0 was 8.6 ± 0.5. This was significantly increased at T1 by 23% to a mean femoral tunnel diameter of 10.6 ± 1.2 mm at the middle portion (*P=0.01*) and by 25% to 10.8 ± 1 mm at the articular portion (*P=0.01*). The mean tibial tunnel diameter increased significantly by 27% to 11.1 ± 1.6 mm at the middle portion (*P=0.01*) and 17% to 10.1 ± 1.2 mm at the articular portion (*P=0.02*).

The differences in tunnel widening between groups are summarized in Table 5. No differences were found between groups with respect to femoral tunnel widening. However,

Table 4 Radiological findings

Variable	Group A		P value	Group B		P value
	T0	T1		T0	T1	
Femoral middle portion ^a	9.28 ± 0.51	12.11 ± 0.91	<i>0.02</i>	8.61 ± 0.5	10.61 ± 1.19	<i>0.01</i>
Femoral articular portion ^a	9.32 ± 0.52	12.01 ± 1.69	<i>0.04</i>	8.59 ± 0.5	10.81 ± 1.01	<i>0.01</i>
Tibial middle portion ^a	9.30 ± 0.51	10.12 ± 0.61	n.s.	8.62 ± 0.5	11.09 ± 1.61	<i>0.01</i>
Tibial articular portion ^a	9.32 ± 0.49	10.09 ± 1.01	<i>0.02</i>	8.60 ± 0.5	10.08 ± 1.22	<i>0.01</i>

Statistically significant differences are reported in bold italics

Tunnel widening from T0 (drill diameter) to T1 (follow-up)

^aData expressed as mean values ± standard deviation

Table 5 Radiological findings

	Femoral side		Tibial side	
	Δ Middle	Δ Articular	Δ Middle	Δ Articular
Group A ^a	2.71 ± 1.21	2.62 ± 1.59	0.81 ± 0.41	0.79 ± 0.78
Group B ^a	2.12 ± 0.91	2.18 ± 0.50	2.42 ± 1.51	1.51 ± 0.81
P value	n.s.	n.s.	<i>0.027</i>	<i>0.027</i>

Statistically significant differences are reported in bold italics

Comparison between mean tunnel widening at T1 (follow-up) of groups

^aValues expressed as difference (Δ) between tunnel diameter at T1 (follow-up) and at T0 (drill diameter); ± standard deviation

there was a significantly larger increases in tunnel widening on the tibial side, at the middle portion, in Group B (2.4 ± 1.5 mm) compared to Group A (0.8 ± 0.4 mm) (*P=0.027*), and also at the articular portion in Group B (1.5 ± 0.8 mm) compared to Group A (0.8 ± 0.8 mm) (*P=0.027*).

Discussion

The main findings of this study were that tibial tunnel widening was significantly greater following ACLR performed with femoral suspensory fixation and a tibial interference screw fixation when compared to the all-inside technique and that there was no significant differences between groups with respect to femoral tunnel widening or clinical outcomes.

The potential reasons for the differences between groups with respect to tibial tunnel widening can be considered with respect to biomechanical and biological issues, respectively. It is recognized that tunnel widening is greater with hamstring tendon grafts when compared to BTB and also that most tunnel widening occurs in the first 6 weeks after surgery. This suggests that reducing the time to graft to bone healing, by improving the biological environment, may reduce the extent of tunnel widening. Bone ingrowth has

been reported to be slowest at the tunnel apertures and this may be a result of the “synovial bathing effect” [27]. It is postulated that retrograde drilling may reduce this effect because it is associated with less subchondral bone fragmentation as well as fewer fracture fragments at the tibial tunnel aperture compared to anterograde drilling [19]. Retrograde drilling may therefore limit the amount of synovial fluid migration from the joint to the bone tunnel [27]. This is partly supported by Lanzetti et al. [13] who reported that when using cortical suspensory fixation, femoral sockets created using an outside-in technique were associated with significantly less widening than those sockets created with a trans-tibial technique. Similarly, the use of a cortical adjustable loop length device, which allows complete filling of sockets by the graft may also reduce the empty space available for synovial fluid migration [24].

Suspensory fixation may offer other biological advantages over interference screw fixation. Several authors have reported that interference screws provide a limited tendon–bone contact area because much of the tunnel circumference is occupied by the screw itself, while adjustable loop systems provide a greater contact zone [15, 29], and allow “four-zone direct graft healing” which has been associated in animal study with the absence of tunnel widening on radiographic and histologic assessments [29]. In contrast, from a biomechanical perspective, it is suggested that extracortical suspensory fixation may actually increase the risk of tunnel widening due to graft micro-motion within the tunnels on the longitudinal axis (the “bungee cord effect”) and transverse axis (the “windshield wiper effect”) [8]. This is therefore a concern with the all-inside technique which uses two adjustable loop suspensory fixation devices, particularly because of recent reports of loop lengthening with adjustable suspensory fixation devices, which may result in increased graft micro-motion. However, some recent biomechanical studies showed no significant loop lengthening using two adjustable loop suspensory devices for femoral tibial fixation [21, 22]. Moreover, no evidence of increased tunnel widening was noted in this study with the all-inside technique, when compared to a standard technique, and this allowed us to reject the study hypothesis.

Bioabsorbable screws are also associated with other disadvantages. Despite their widespread use, they are well recognized for their association with migration, cyst formation, biological/immunological responses to the screw itself, and tunnel widening [2, 20]. However, to the knowledge of the authors, specific data on tunnel widening with the bioabsorbable DeltaScrew (Arthrex, Naples, FL, USA) used for tibial fixation, in association with suspensory femoral fixation, has not been published. It should be emphasized that bioabsorbable screws should not be considered as a single category because different biomaterial compositions may be associated with different degrees of

tunnel widening. Karikis et al. [11], in a study of patients undergoing ACLR with interference screw fixation in both femoral and tibial tunnels, demonstrated a reduction in the tibial tunnel diameter at a mean follow-up of 5 years when a bioabsorbable screw was used (Matryx; ConMed Linvatec, Largo, FL, USA). It is not possible to determine whether the differences in tibial tunnel widening between the current study and the findings of Karikis et al. are due to the material properties of the respective screws or due to difference in other aspects of the surgical technique, including the femoral fixation or the length of follow-up.

There is a complex interplay of biomechanical and biological factors that influence tunnel widening after ACLR. Although the exact mechanisms through which tunnel widening occurred in the different groups in this study cannot be determined, it can be concluded that tibial tunnel widening in all-inside ACLR is significantly lower than in patients undergoing tibial fixation with a bioabsorbable screw. It could also be stated that the use of sockets instead of full tunnels confers preservation of bone for revision surgery but this was not specifically evaluated in the current study.

This study demonstrated excellent overall clinical results in both groups. However, it is unlikely that it was adequately powered to detect a difference in clinical outcomes between groups. Despite that it is important to highlight that the outcomes of ACLR in the all-inside group showed excellent return to sport, knee stability, low graft rupture rate and a high Lysholm, Tegner and IKDC score. This is in keeping with other authors reporting the outcomes of all-inside ACLR.

This study has some limitations. The primary limitation was the retrospective design, which has inherent limitations due to the risk of bias and confounding. However, patients included in both groups were not significantly different demographically. The assumption that the tunnel diameter at T0 was the same as the drill diameter used could also be considered a limitation but this choice was determined by the reliability between drill diameter and CT measurements in the early post-operative period reported by previous authors [9, 30], and the benefit of minimizing radiation exposure. The overall study population was relatively small but this was based upon a sample size calculation and inclusion of an adequate number of patients to evaluate tunnel widening. A further limitation was that the median follow-up period was only 2 years. This was considered to be appropriate because Fink et al. [6] and Harris et al. [7] reported that most tunnel enlargement occurs within the first 6 weeks after surgery, and Mayr et al. [18] reported that the tunnels usually increased in size up to 6 months postoperatively, and decreased slightly after a year.

The clinical relevance of this work lies in the rebuttal of concerns arising from biomechanical studies regarding the

possibility of increased tunnel widening with an all-inside technique.

Conclusions

Tibial tunnel widening after ACLR using hamstring tendon autograft is significantly greater with suspensory femoral fixation and a bioabsorbable tibial interference screw when compared to an all-inside technique at a median follow-up of 2 years.

Funding No external funding was used.

Compliance with ethical standards

Conflict of interest Edoardo Monaco, Andrea Ferretti and Angelo De Carli declares to be consultant for Arthrex.

Ethical approval All procedure performed in the study involving humans participants were in accordance with the ethical standards of the institutional research committee and with the 1964 Helsinki declaration and its later amendments or comparable ethical standards.

References

- Burnham JM, Malempati CS, Carpiaux A, Ireland ML, Johnson DL (2017) Anatomic femoral and tibial tunnel placement during anterior cruciate ligament reconstruction: anteromedial portal all-inside and outside-in techniques. *Arthrosc Tech* 6(2):e275–e282
- Colombet P, Graveleau N, Jambou S (2016) Incorporation of hamstring grafts within the tibial tunnel after anterior cruciate ligament reconstruction: magnetic resonance imaging of suspensory fixation versus interference screws. *Am J Sports Med* 44(11):2838–2845
- Crespo B, Aga C, Wilson KJ, Pomeroy SM, LaPrade RF, Engbretsen L, Wijdicks CA (2014) Measurements of bone tunnel size in anterior cruciate ligament reconstruction: 2D versus 3D computed tomography model. *J Exp Orthop* 1(1):2
- De Beus A, Koch JE, Hirschmann A, Hirschmann MT (2017) How to evaluate bone tunnel widening after ACL reconstruction—a critical review. *Muscles Ligaments Tendons J* 7(2):230–239
- Fahey M, Indelicato PA (1994) Bone tunnel enlargement after anterior cruciate ligament replacement. *Am J Sports Med* 22(3):410–414
- Fink C, Zapp M, Benedetto KP, Wolfgang H, Hoser C, Rieger M (2001) Tibial tunnel enlargement following anterior cruciate ligament reconstruction with patellar tendon autograft. *Arthroscopy* 17(2):138–143
- Harris NL, Indelicato PA, Bloomberg MS, Meister K, Wheeler DL (2002) Radiographic and histologic analysis of the tibial tunnel after allograft anterior cruciate ligament reconstruction in goats. *Am J Sports Med* 30(3):368–373
- Höher J, Möller HD, Fu FH (1998) Bone tunnel enlargement after anterior cruciate ligament reconstruction: fact or fiction? *Knee Surg Sports Traumatol Arthrosc* 6(4):231–240
- Iorio R, Di Sanzo V, Vadalà A, Conteduca J, Mazza D, Redler A et al (2013) ACL reconstruction with hamstrings: how different technique and fixation devices influence bone tunnel enlargement. *Eur Rev Med Pharmacol Sci* 17(21):2956–2961
- Irrgang JJ, Ho H, Harner CD, Fu FH (1998) Use of the international knee documentation committee guidelines to assess outcome following anterior cruciate ligament reconstruction. *Knee Surg Sports Traumatol Arthrosc* 6(2):107–114
- Karikis I, Ejerhed L, Sernert N, Rostgård-Christensen L, Kartus J (2017) Radiographic tibial tunnel assessment after anterior cruciate ligament reconstruction using hamstring tendon autografts and biocomposite screws: a prospective study with 5-Year follow-up. *Arthroscopy* 33(12):2184–2194
- Kim SG, Kurosawa H, Sakuraba K, Ikeda H, Takazawa S, Takazawa Y (2005) Development and application of an inside to-out drill bit for anterior cruciate ligament reconstruction. *Arthroscopy* 21(8):1012
- Lanzetti RM, Monaco E, De Carli A, Grasso A, Ciompi A, Sigillo R, Argento G, Ferretti A (2016) Can an adjustable-loop length suspensory fixation device reduce femoral tunnel enlargement in anterior cruciate ligament reconstruction? A prospective computer tomography study. *Knee* 23(5):837–841
- Lubowitz JH, Ahmad CS, Anderson K (2011) All-inside anterior cruciate ligament graft-link technique: Second generation, no-incision anterior cruciate ligament reconstruction. *Arthroscopy* 27(5):717–727
- Lubowitz JH, Schwartzberg R, Smith P (2015) Cortical suspensory button versus aperture interference screw fixation for knee anterior cruciate ligament soft-tissue allograft: a prospective, randomized controlled trial. *Arthroscopy* 31(9):1733–1739
- Marchant MH Jr, Willimon SC, Vinson E et al (2010) Comparison of plain radiography, computed tomography, and magnetic resonance imaging in the evaluation of bone tunnel widening after anterior cruciate ligament reconstruction. *Knee Surg Sports Traumatol Arthrosc* 18(8):1059–1064
- Mayr R, Heinrichs CH, Eichinger M, Coppola C, Schmoelz W, Attal R (2015) Biomechanical comparison of 2 anterior cruciate ligament graft preparation techniques for tibial fixation: adjustable-length loop cortical button or interference screw. *Am J Sports Med* 43(6):1380–1385
- Mayr R, Smekal V, Koidl C, Coppola C, Fritz J, Rudisch A, Kranewitter C, Attal R (2017) Tunnel widening after ACL reconstruction with aperture screw fixation or all-inside reconstruction with suspensory cortical button fixation: volumetric measurements on CT and MRI scans. *Knee* 24(5):1047–1054
- McAdams TR, Biswal S, Stevens KJ, Beaulieu CF, Mandelbaum BR (2008) Tibial aperture bone disruption after retrograde versus antegrade tibial tunnel drilling: a cadaveric study. *Knee Surg Sports Traumatol Arthrosc* 16(9):818–822
- Mermerkaya MU, Atay OA, Kaymaz B, Bekmez S, Karaaslan F, Doral MN (2014) Anterior cruciate ligament reconstruction using a hamstring graft: a retrospective comparison of tunnel widening upon use of two different femoral fixation methods. *Knee Surg Sports Traumatol Arthrosc* 23(8):2283–2291
- Monaco E, Bachmaier S, Fabbri M, Lanzetti RM, Wijdicks CA, Ferretti A (2018) Intraoperative workflow for all-inside anterior cruciate ligament reconstruction: an in vitro biomechanical evaluation of preconditioning and knot tying. *Arthroscopy* 34(2):538–545
- Monaco E, Fabbri M, Lanzetti RM, Del Duca A, Labianca L, Ferretti A (2017) Biomechanical comparison of four coupled fixation systems for ACL reconstruction with bone socket or full-tunnel on the tibial side. *Knee* 24(4):705–710
- Mulcahey MK, David TS, Epstein DM, Alaia MJ, Montgomery KD (2014) Transtibial versus anteromedial portal anterior cruciate ligament reconstruction using soft-tissue graft and expandable fixation. *Arthroscopy* 30(11):1461–1467

24. Osti M, Krawinkel A, Hoffelner T, Benedetto KP (2015) Quantification of tibial bone loss in antegrade versus retrograde tunnel placement for anterior cruciate ligament reconstruction. *Int Orthop* 39(8):1611–1614
25. Prentice HA, Lind M, Mouton C, Persson A, Magnusson H, Gabr A, Seil R, Engebretsen L, Samuelsson K, Karlsson J, Forssblad M, Haddad FS, Spalding T, Funahashi TT, Paxton LW, Maletis GB (2018) Patient demographic and surgical characteristics in anterior cruciate ligament reconstruction: a description of registries from six countries. *Br J Sports Med* 52(11):716–722
26. Robbrecht C, Claes S, Cromheecke M, Mahieu P, Kakavelakis K, Victor J, Bellemans J, Verdonk P (2014) Reliability of a semi-automated 3D-CT measuring method for tunnel diameters after anterior cruciate ligament reconstruction: a comparison between soft-tissue single-bundle allograft vs. autograft. *Knee* 21(5):926–931
27. Rodeo SA, Arnoczky SP, Torzilli PA, Hidaka C, Warren RF (1993) Tendon healing in a bone tunnel. A biomechanical and histological study in the dog. *J Bone Jt Surg Am* 75(12):1795–1803
28. Sabzevari S, Rahnemai-Azar AA, Shaikh HS, Arner JW, Irrgang JJ, Fu FH (2017) Increased lateral tibial posterior slope is related to tibial tunnel widening after primary ACL reconstruction. *Knee Surg Sports Traumatol Arthrosc* 25(12):3906–3913
29. Smith PA, Stannard JP, Pfeiffer FM, Kuroki K, Bozynski CC, Cook JL (2016) Suspensory versus interference screw fixation for arthroscopic anterior cruciate ligament reconstruction in a translational large-animal model. *Arthroscopy* 32(6):1086–1097
30. Vadalà A, Iorio R, De Carli A, Argento G, Di Sanzo V, Conteduca F et al (2007) The effect of accelerated, brace free, rehabilitation on bone tunnel enlargement after ACL reconstruction using hamstring tendons: a CT study. *Knee Surg Sports Traumatol Arthrosc* 15(4):365–371